

## Histopathological Study of Splenectomy Specimens with Correlation with Age, Sex, and Cause of Splenectomy.

Dr Hiral Patel<sup>1\*</sup>, Dr Hansa Goswami<sup>2</sup>, Dr Mehul Patel<sup>3</sup>

<sup>1, 3</sup> Third Year Resident, <sup>2</sup> Professor & Head, Department of Pathology, B. J. Medical College, Ahmedabad.

### Abstract:

Spleen is mysterious organ. It can be troublesome specimen for surgical pathologist due to discordance between patient's clinical condition and perceived finding. The weight of spleen is about 150 grams and lies beneath 9<sup>th</sup> to 12<sup>th</sup> thoracic rib in healthy adult and between fundus of stomach & diaphragm. It composed of red pulp (76-79%) and white pulp (5-20%) which are separated by marginal zone. A total of 100 cases were studied at histopathology section of our laboratory during the period of January 2015 to December 2015. The specimens were received in 10% neutral buffer formalin with duly filled request form. All specimens were examined macroscopically. After routine processing the sections were stained with routine haematoxylin and eosin stain. The most common age group to be affected is 3<sup>rd</sup> decade (29%), next was 4<sup>th</sup> decade (23%) with slightly male predominance. Male: female ratio is 1.3:1. Most common cause for splenectomy was portal hypertension (33%) followed by trauma (15%). Most common microscopic finding is fibrocongestive splenomegaly (68%) which is correlated with clinical and radiological finding. In adult Portal hypertension as a hepatic cause and in paediatric age group thalassemia is the most common indication for splenectomy.

**Key Words:** Fibrocongestive splenomegaly, Portal Hypertension, Splenectomy

### Introduction:

The weight of spleen is about 150 grams and lies beneath 9<sup>th</sup> to 12<sup>th</sup> thoracic rib in healthy adult and between fundus of stomach & diaphragm. It composed of red pulp (76-79%) and white pulp (5-20%) which are separated by marginal zone. Spleen is mysterious organ. It can be troublesome specimen for surgical pathologist due to discordance between patient's clinical condition and perceived finding.<sup>1, 2</sup>



### Aims and Objectives:

- To study the etiological factors responsible for splenectomy
- To study the relation of age and sex with splenectomy
- To correlate the clinical diagnosis with histopathological diagnosis.

### Materials and Method:

This is the descriptive study of examination of splenectomy specimens. A total of

\* Corresponding Author:

Dr Hiral Patel

E-mail: hiralchakupatel156@gmail.com

100 cases were studied at histopathology section of our laboratory during the period of January 2015 to December 2015. The specimens were received in 10% neutral buffer formalin with duly filled request form. All specimens were examined macroscopically. After routine processing the sections were stained with routine haematoxylin and eosin stain.

**Result:**

This study was carried out in one of the largest tertiary care hospital during the period of January 2015 to December 2015. A total of 100 specimens of spleen were studied. The most common age group to be affected is 3<sup>rd</sup> decade (29%), next was 4<sup>th</sup> decade (23%) with slightly male predominance. male:female ratio is 1.3:1 (Table 1).<sup>3,4</sup>

**Table-1 Age wise incidence**

Age of patients (years)	Male	Female	Total	Percentage (%)
2-10	5	2	7	7
11-20	7	6	13	13
21-30	15	14	29	29
31-40	18	15	23	23
41-50	6	4	10	10
51-60	3	2	5	5
61-65	2	1	3	3
Total	56	44	100	100

Most common cause for splenectomy was portal hypertension (33%) followed by trauma (15%) (Table-2).

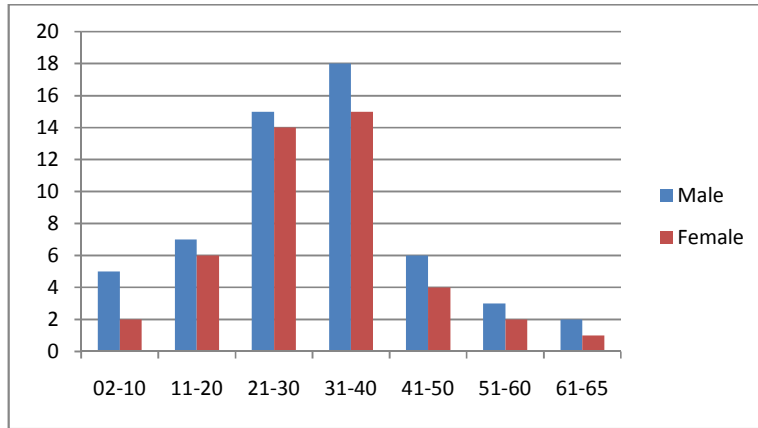
**Table-2 Clinical cause of Splenomegaly**

Provisional Diagnosis/Indication	Number	Percentage (%)
Portal hypertension	33	33
Trauma	15	15
No cause identified	11	11
Hypersplenism/pancytopenia	11	11
Thalassemia	11	11
ITP	6	6
Hydatid cyst	5	5
Abscess	2	2
Autoimmune Haemolytic Anaemia (AIHA)	1	1
Hemoglobinopathy	2	2
Myeloproliferative disease	1	1
TB	1	1
Splenic vein thrombosis	1	1
Total	100	100

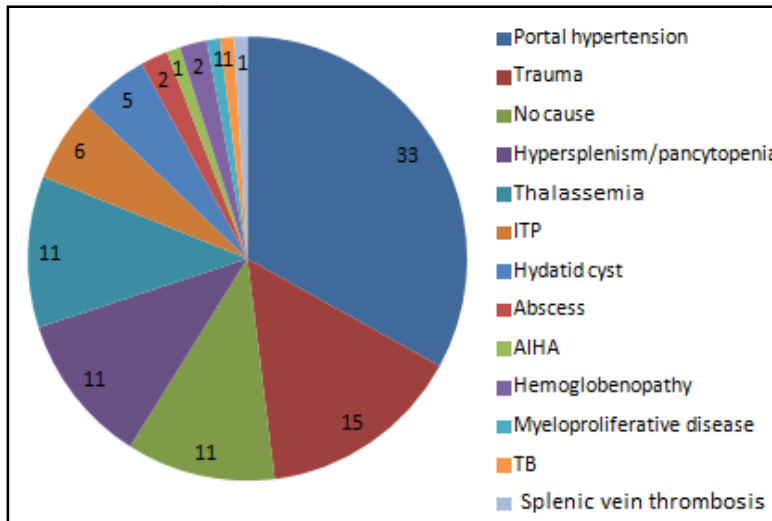
Thalassemia was most common cause of splenectomy in 2-10 year age group. Portal hypertension and trauma being the leading cause of splenectomy in 3<sup>rd</sup> decade. Idiopathic Thrombocytopenic Purpura (ITP) was found out to be most common in 4<sup>th</sup> decade.

Lymphoma is common in old age as expected.<sup>6,7</sup> (Table-3).

**Chart 1 Age wise incidence**



**Chart 2 Clinical causes of Splenomegaly**



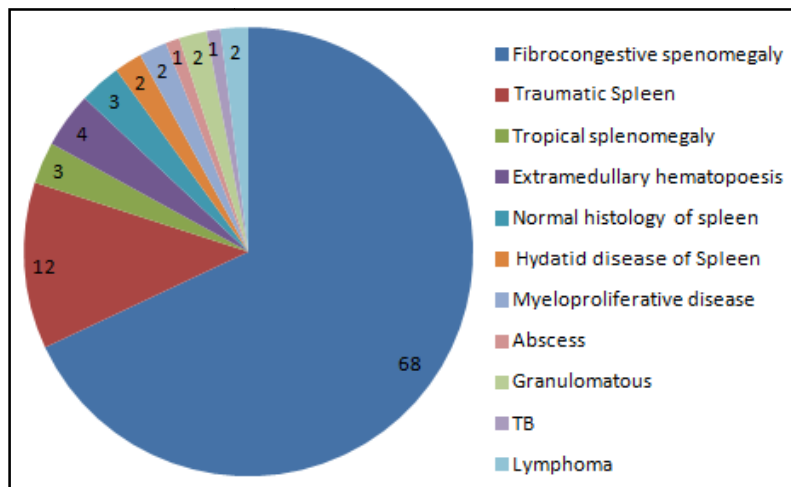
**Table-3 Correlation of age with specific clinical cause**

Age of Patient	Cause	No of Patient
2-10 years	Thalassemia	11
11-20 years	Cirrhosis	15
21-30 years	Portal hypertension	32
31-41 years	ITP	6

Most common microscopic finding is fibrocongestive splenomegaly (68%) which is correlated with clinical and radiological finding (Table-4).<sup>3,4,5</sup>

**Table-4 Histopathological Examination**

Diagnosis	Total no of patients	%
Fibrocongestive splenomegaly	68	68
Traumatic spleen	12	12
Tropical splenomegaly <sup>8</sup>	3	3
Splenomegaly with Extramedullary Haematopoiesis	4	4
Normal histology of spleen	3	3
Hydatid disease of spleen	2	2
Extensive myeloid metaplasia s/o Myeloproliferative disease	2	2
Abscess formation of spleen	1	1
Granulomatous inflammation with Abscess formation	2	2
TB spleen <sup>9</sup>	1	1
Lymphoma of spleen	2	2
<b>Total</b>	<b>100</b>	<b>100</b>

**Chart 3 Histopathological Examination****Discussion:**

This study involves 100 cases and focused on histopathological correlation of clinical findings. Histopathological study and audit of the spleen in Nigerians was also carried out by Kayode et. al<sup>10</sup> during the period of 18 years between 1988 and 2005. Only 123 specimens of spleen were received. 119 had adequate data to be included in this study. He found male predominance with male:female ratio is 1.77:1; which is correlated with the present study.

Kayode et.al<sup>10</sup> studied the most common age group to be affected is 3<sup>rd</sup> decade (17.89%), which is correlated with our study as we found 29 % in the 3<sup>rd</sup> decade. The incidence decreased after age of 60.

In present study most common cause of splenomegaly as well as indication of

splenectomy comes out to be hepatic-portal hypertension is very common in Gujarat, Rajasthan. In case of portal hypertension, development of portosystemic collateral, which shunt blood away from the liver. Thus less blood reaches the liver when portal flow increases (diminished hepatic reserve). In addition, toxic substances from the intestine are shunted directly to the systemic circulation, contributing to portosystemic encephalopathy. Venous congestion within visceral organs due to portal hypertension contributes to ascites via altered Starling forces. Splenomegaly and hypersplenism commonly occur as a result of increased splenic vein pressure.<sup>11</sup> Thrombocytopenia, leukopenia and less commonly, haemolytic anaemia may result.

### Conclusion:

In adult Portal hypertension as a hepatic cause and in paediatric age group thalassaemia is the most common indication for splenectomy. A pathologist should be vigilant for lymphoma as it can be underdiagnosed as reactive lesion.

### References:

1. Rosai J: Ackerman's Surgical Pathology (9<sup>th</sup> Ed); 2004: 22: 2019-2046.
2. Sternberg S: Diagnostic Surgical pathology (4<sup>th</sup> Ed) : Lippincott Williams & Wilkins, 2004 : 18:849-878
3. Shah S., Gosai R, Gonsai R.N.; Histopathological review of spleen specimens. Lancet Apr 19 1997; 349(9059): 1178.
4. Madeleine D. Kraus; MD Seminars in Diagnostic Pathology; Vol 20, No 2 (May), 2003:84-93
5. Weichselbaum, A. Beitrage zur Geschwulstlehre. Ein gangioses Neurom der Nebenniere. Virchows Arch. f. patk. Anat., i88i, 85, 554-567.
6. Ahman DL, Kiely JM, Harrison EG, Payne WS. Malignant lymphoma; A review of 49 cases in which the diagnosis was made at splenectomy. Cancer, 1966 Apr; 19(4) : 461-9.
7. Smith C.E. and Rusk G. Y.; Endothelioma of spleen. A study of 2 cases, with review of the literature of primary malignancy of the spleen. Arch. Surg., 1923, 7, 371-414.
8. Bates I, Bedu-Addo G, Rutherford T, Bevan D. Splenic lymphoma with villous lymphocytes in tropical west Africa. Lancet 1992; 340: 575-77.
9. Aranha GV, Gold S, Grace TB; Hemangiosarcoma of spleen; Surg Oncol 1976, 8: 481-487
10. Kayode A. Adelusola, Stephen A. Osasan, Olusegun A. Afolabi: Histopathological study and audit of the spleen in Nigerians; African Journal of Health Sciences, Vol. 14, No. 3-4, July-Dec, 2007, 195-200.
11. Bosch J, Pizcueta P., Feu F. Pathophysiology of Portal Hypertension, Gastroenterol Clin. North Am. 1992 March; 21(1): 1-14.