

## Evan's Syndrome: Case Series with Review of Literature

**Dr Dhara Patel<sup>1</sup>, Dr Sangita Shah<sup>2</sup>, Dr Nidhi Bhatnagar<sup>3</sup>, Dr Mamta Shah<sup>4</sup>, Dr Garima Thakkar<sup>5\*</sup>, Dr Rajvi Vora<sup>6</sup>**

<sup>1</sup> Senior resident doctor, Department of Immunohaematology and blood transfusion, B J Medical College and Civil Hospital, Ahmedabad.

<sup>2,4</sup> Assistant Professor, Department of Immunohaematology and blood transfusion, B J Medical College and Civil Hospital, Ahmedabad.

<sup>3</sup> Associate Professor & Head of Department, Department of Immunohaematology and blood transfusion, B J Medical College and Civil Hospital, Ahmedabad.

<sup>5,6</sup> Resident doctor, Department of Immunohaematology and blood transfusion, B J Medical College and Civil Hospital, Ahmedabad.

**Corresponding Author:** Dr Garima Thakkar

**Email:** garimathakkar4870@gmail.com



### Abstract

Evans syndrome is a rare autoimmune disease in which an individual's antibodies attack the body's own red blood cells and platelets. It is characterised by simultaneous or sequential development of Immune Thrombocytopenic Purpura (ITP) and Autoimmune Hemolytic Anemia (AIHA) with positive Direct Antiglobulin test (DAT). AIHA can be cold, warm or mixed type depending on the type of antibody. 80% of total AIHA cases are warm AIHA. Warm AIHA is mostly caused by IgG antibody which reacts at 37<sup>0</sup> C. Warm AIHA is associated with classical case of Evan's syndrome. Some variants of Evan's syndrome are associated with leucocytosis. The current article discusses 3 cases of Evan's syndrome, all presenting differently - Classical Evan's syndrome, Evan's syndrome associated with leucocytosis and Evan's syndrome associated with neuropathic pain. In this case series, pathophysiology, workup done at blood centre and blood component transfusion support in patients with Evan's syndrome has been discussed.

**Keywords:** Evan's syndrome, Anemia, Autoimmune

### Introduction

Evan's syndrome (ES) is an uncommon condition characterised by the combination (either simultaneous or sequential) of direct antiglobulin test positive autoimmune haemolytic anaemia (AIHA), immune thrombocytopenia (ITP) and/or immune neutropenia in the absence of a known underlying etiology. The syndrome was first described by Robert Evans in 1951 when he demonstrated a relationship between primary immune thrombocytopenia and acquired haemolytic anemia. The combination of direct Coombs positive haemolytic anaemia and immune thrombocytopenia without any obvious underlying aetiology defines patients with ES.<sup>1</sup>

ES is a very rare disorder and very little is known about its epidemiology. A study was conducted in Denmark where 242 patients were monitored for 40 years. Rarity of disorder was confirmed by incidence rate of 1.8million/year. Mean age of Evans is 58 years. Females are affected more in comparison to male.<sup>2</sup>

ES is more common in the paediatric population than in adults and is often associated with underlying autoimmune disease, connective tissue disease, immune deficiency disorders, lymphoproliferative disorders, or malignancy of the immune system. ES is classified as either primary or secondary, depending on the presence of underlying autoimmune disease or connective tissue disease. Associated diseases include systemic lupus erythematosus (SLE), autoimmune lymphoproliferative syndrome (ALPS), and immune deficiency disorders such as common variable immunodeficiency (CVID), or lymphoid malignancy, including non-Hodgkin's lymphoma (NHL) and chronic lymphocytic leukemia (CLL).<sup>3</sup> The current article discusses 3 cases, all presenting differently. Management can be started early if correct diagnosis is made.

### Case 1

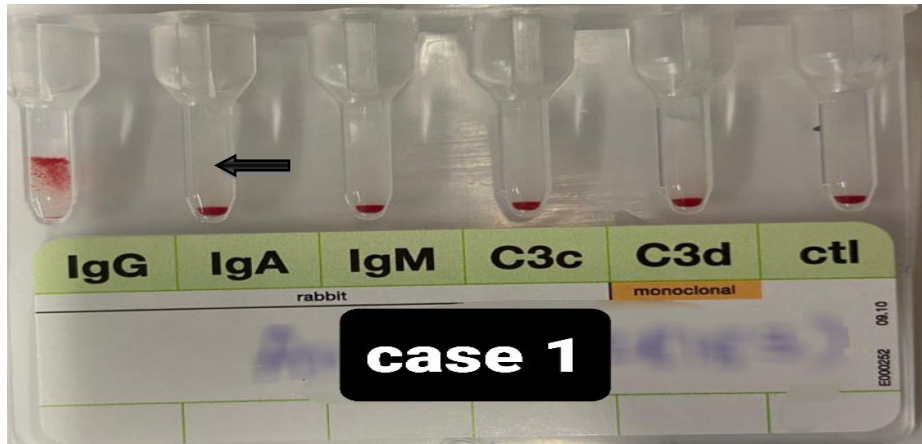
A 28-year-old female arrived in emergency department with chief complaints of general malaise, nasal bleeding, mucosal bleeding, decreased appetite, black coloured stool and easy fatigability since 10 days. On the day of admission, patient had low Hemoglobin and platelet count.

**Table – 1. Investigations and details of transfusion – Case 1**

Investigations	On day of admission	Day 3	Day 5	Day 7	On day of discharge
Hb (gm/dl)	5.0	6.3	8.1	8.3	8.5
Platelet count	52 x10 <sup>3</sup>	58 x10 <sup>3</sup>	62x10 <sup>3</sup>	64x10 <sup>3</sup>	75 x10 <sup>3</sup>
DAT	Grade II positive	-	Grade II positive	-	-
IAT	Grade I positive	-	Negative	-	-
Monospecific (CAT)	IgG positive (Image 1)	-	-	-	-
Auto control (CTT)	RT- Negative 37°C - Positive (+2) 4°C - Negative				
ANA Profile	Presence of SM/RNA antibody (strong suggestive of ES)	-	-	-	-
Bone marrow biopsy		RBC: Microcytic Hypochromic Platelets: Decreased Reticulocytes: Increased Cellular Impression S/o ITP			
Peripheral smear		RBC: Microcytic Hypochromic Platelets: Thrombocytopenia WBC: normal range			
Blood component transfusion	PRC – 1 unit RDP – 3 unit	RDP – 3 unit	PRC – 1 unit	RDP – 2 unit	

**DAT-** Direct antiglobulin test, **IAT-** Indirect antiglobulin test, **CAT-** Column agglutination test, **CTT-** Conventional test tube method, **ANA-** Anti nuclear antibody, **PRC-** Packed red cells, **RDP-** Random donor platelet, **ITP-** Immune thrombocytopenic purpura

Request for transfusion of 3 units of packed red blood cells (PRBC) and 6 units of platelet concentrate was received. Blood grouping, antibody screening and cross matching were done by blood centre. Direct and Indirect Antiglobulin Test was found positive while doing work up. Monospecific DAT was positive for IgG (**Table1**). To find compatible blood unit for this patient, crossmatch was done with 20 PRBC units out of which only 3 units were compatible. Out of them 2 units were transfused to the patient.

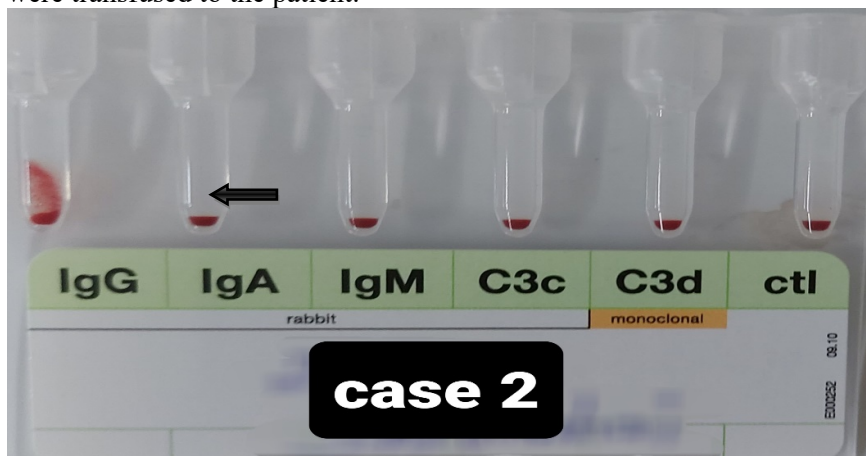


**Figure 1 – Monospecific (column agglutination test) for CASE 1 – positive (IgG)**

Results of bone marrow biopsy and ANA profile were strongly suggestive of the diagnosis of classical ES. After blood component transfusion patient showed marked improvement in symptoms as well as laboratory parameters. Other treatment given was, injectable corticosteroids for 5 days followed by oral Methylprednisolone, Tranexamic acid and Botox to control epistaxis and gum bleeding and other vitamins and mineral supplements.

## Case 2

A 63-year-old male arrived at the Emergency department with sign and symptoms of giddiness, generalized weakness, low grade fever, cough, pedal edema, mild episodes of hematemesis and Melaena. On the day of admission, patient had low hemoglobin, platelet count and leukocytosis. Request for transfusion of 2 units of packed red blood cells and 10 units of platelet concentrate was received. Blood grouping, antibody screening and cross matching were done by blood centre. Direct Antiglobulin Test was positive while doing work up. In Monospecific DAT, IgG was positive (**Table 2**). To find compatible blood unit for this patient, crossmatch was done and 2 compatible units of packed red cells were transfused to the patient.



**Figure 2 Monospecific (column agglutination test) for CASE 2 – Positive (IgG)**

**Table – 2 Investigations and details of transfusion – Case 2**

Investigations	ON DAY OF ADMISSION	DAY 4	ON DAY OF DISCHARGE
Hb	7 gm/dl	7.2gm/dl	9.8 gm/dl
TLC	16.9x10 <sup>3</sup>	19x10 <sup>3</sup>	20x10 <sup>3</sup>
Platelet Count	22x10 <sup>3</sup>	75x10 <sup>3</sup>	75x10 <sup>3</sup>
DAT	Grade II positive	-	-
IAT	Negative	-	-
Monospecific (CAT)	IgG positive(Image 2)	-	-
Autocontrol (CTT)	RT- Negative 37°C - Negative 4°C – Negative		
Peripheral smear study	RBC: normocytic normochromic Platelets: Large Reticulocytes: Increased		
Bone marrow biopsy (done before 2 years)	Mild hypercellularity in all lineage of cells. Severe thrombocytopenia. Lymphocytosis is seen but morphology is normal. Possibility of ES.		
Blood component transfusion	PRC – 1 unit RDP – 4 unit	PRC – 1 unit RDP – 4 unit	

TLC- Total leukocyte count

**Past History:** Previously before 2 years, patient was treated for the similar symptoms at tertiary care cancer hospital.

From above described clinical presentation and investigations, the patient was diagnosed as warm AIHA with thrombocytopenia (Evan's Syndrome) associated with leukocytosis. Possibility of lymphoma and chronic lymphocytic leukemia was ruled out by bone marrow biopsy.

This time, the patient was admitted due to relapse of the disease. Along with transfusions patient was also kept on injectable corticosteroids followed by oral corticosteroids, immune suppressants like AZORAM and DANAZOL. After 7 days of hospital stay and appropriate treatment, patient got discharge on 7<sup>th</sup> day.

### Case 3

A 38 year old woman admitted in emergency dept with complain of burning pain in both feet since 7 days, weakness, constipation, nausea and vomiting since 1 month. Patient was known case of Evan's Syndrome since 5 years.

**Past history:** History of transfusion of 4 units of packed red cells at our institute 4 years back. At the same time patient was diagnosed to have Evan's syndrome by Bone marrow biopsy finding at tertiary care cancer hospital.

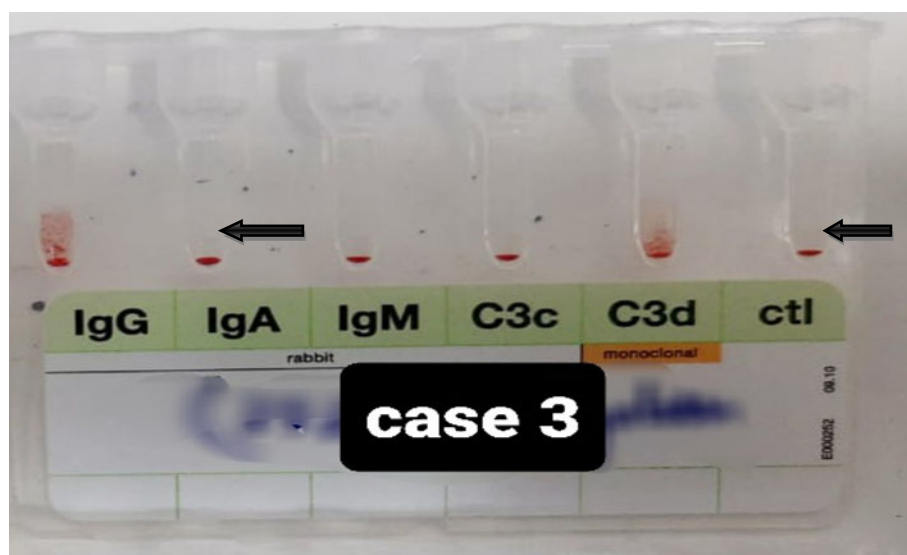


Figure 3 Monospecific (Column agglutination test) for CASE 3 - Positive for IgG and C3d

Table – 3 Investigation details – Case 3

Investigations	On day of admission	2 <sup>nd</sup> day of admission	On day of discharge
Hb	11.0gm/dL	12.9 gm/dl	12.6 gm/dl
Platelet count	$15 \times 10^3$	$22 \times 10^3$	$39 \times 10^3$
DAT	-	Grade II positive	-
IAT	-	Grade II positive	-
Monospecific (CAT)	-	Presence of IgG and C3d	-

As treatment with Immune suppressants like Azoram and Danazol was going on, no need of transfusion was there for this patient of ES as hemoglobin and platelet count was almost near to normal range and patient was stable clinically.

### Discussion

EVANS syndrome (ES) is uncommon disorder defined by Robert Evans in 1951 when he studied relationship between autoimmune hemolytic anemia (AIHA) and immune thrombocytopenic purpura (ITP).<sup>1</sup>

Evans described the diagnosis criteria of ES<sup>1</sup>:

- Presence of anemia
- Reticulocytosis
- Increased blood bilirubin and fecal urobilinogen
- No family history of hemolytic diseases,
- Evidence of antibodies against erythrocytes at 37°C,
- Hemolysis of transfused erythrocytes,
- Presence of purpura,
- Prolonged bleeding time,
- Bone marrow aspiration with normal or increased number of megakaryocytes and

Absence of exogenous toxic agents or a baseline disease.

ES is listed as a “rare disease” by the Office of Rare Diseases (ORD) of the National Institutes of Health (NIH). There is no preferential distribution of Evans syndrome by age, gender, or ethnic group. Its

chronic course is characterized by recurrent relapses and remissions. The etiology is unknown. However, suggested basic pathology is the role of non cross-reacting auto antibody against red cells and platelets.<sup>4</sup> There is evidence to support abnormalities in both cellular and humoral immunity in Evans syndrome. Both CD4 and CD8 lymphocytes were reduced; increased constitutive production of interleukin-10 and interferon- $\gamma$  caused activation of autoreactive, antibody-producing B cells.

Patients may present with AIHA or ITP either separately or concomitantly. Neutropenia occurs in up to 55% of patients at presentation, or pancytopenia (14%). The development of the second cytopenia may occur months to years after the first immune cytopenia and may delay diagnosis. Usual features of hemolytic anemia: pallor, lethargy, jaundice, heart failure in severe cases; and features of thrombocytopenia i.e: petechiae, bruising, mucocutaneous bleeding may be present. The lymphadenopathy and organomegaly (hepatomegaly and/or splenomegaly) may be chronic or intermittent and in some cases may only be apparent during episodes of acute exacerbation.<sup>5-8</sup>

In our study clinical presentation among all 3 patients was different, patient with classical ES had anemia and thrombocytopenia, among other two patients with relapse of disease, one had anemia, thrombocytopenia with leukocytosis and another had neuropathic pain only.

Momin *et al* has shown a case of 56 year old female with ES and shown diagnostic importance of peripheral blood picture, reticulocyte count and direct antiglobulin test in every patient presenting with anemia and / or thrombocytopenia to rule out hemolytic anemia and thrombocytopenia of autoimmune etiology in his study.<sup>9</sup>

Evidence has been there that antibodies found in the patients are reactive at 37°C. So, mainly AIHA is warm AIHA. Presence of purpura, mucosal bleeding, epistaxis and menorrhagia were related to ITP excluding other differential diagnosis. Mostly the antibodies are detected against RBCs only and those are IgG.

Michel *et al* has shown detection of antiplatelet antibodies (APA), 70% patients had positive circulating and/or fixed IgG APA, anti-IIb-IIIa (60% of the cases) were predominantly found antibodies in combination with anti-IbIX in 2 patients. In his study 43% patients had IgG positive and 53% had positive IgG + C3d on monospecific DAT result.<sup>10</sup>

In our study monospecific DAT result in one patient was IgG and C3d positive and in two patient it was IgG positive only.

Jordan *et al* has shown detection of Anti *En<sup>a</sup>* autoantibody was in patient of ES. Anti *En<sup>a</sup>* autoantibody reacts with high incidence antigens on glycoprotein A (GPA), MN antigen carrying molecule. This antibody can cause hemolytic transfusion reaction.<sup>11</sup>

Treatment modalities of ES include mainly blood product transfusions. According to the need packed red blood cells, Random donor platelets are transfused to patients and that have reported marked improvement in the patients' clinical condition, though relapse episodes are common in ES.

Therapeutic plasma exchange (TPE) is the third line of treatment for ES, but it can be considered in refractory conditions after trying all treatment modalities. There are evidences where TPE was done in ES and was found helpful.<sup>12</sup>

Different drugs used for treatment of ES are corticosteroids, danazol, azoram, rituximab, IvIg along with the frequent blood products transfusion according to the need.

Scarce reports have documented the use of allogenic hematopoietic stem cell transplantation (HSCT) in ES. The main benefit of allogeneic HSCT is that it currently constitutes the only curative treatment option for ES by resetting the immune system.<sup>13</sup> Thus, this therapy could be a valuable alternative for patients with multiple relapses, with severe complications affecting their quality of life and/or if a lack of response to immunosuppressive drugs exists.

Oyama *et al* has shown a role of allogenic HSCT with a conditioning regimen of cyclophosphamide, 200 mg/kg plus anti-thymocyte globulin at 90 mg/kg in refractory EVANS syndrome in an adult patient treated with multiple interventions. Three months after transplant, antibodies against erythrocytes and

platelets were negative with 100% chimerization. He maintained complete remission for the 30 months of follow-up.<sup>14</sup>

## Conclusion

Though it is very difficult as a transfusion medicine specialist to get compatible blood units for the patients with EVANS syndrome, proper work up and with the role of supportive treatment we can give compatible best match blood units to the patients and can improve patient's clinical condition. Relapse is very common in this disease so long term follow up is also essential for this chronic relapsing disease.

## References

1. Evans RS, Takahashi K, Duane RT, Payne R, Liu C. Primary thrombocytopenic purpura and acquired hemolytic anemia; evidence for a common etiology. *AMA Arch Intern Med.* 1951;87(1):48-65. <http://dx.doi.org/10.14740/jh222w>
2. Hansen DL, Möller S, Andersen K, Gaist D, Frederiksen H. Evans syndrome in adults - incidence, prevalence, and survival in a nationwide cohort. *Am J Hematol.* 2019 Oct;94(10):1081-1090. doi: 10.1002/ajh.25574. Epub 2019 Aug 9. PMID: 31292991.
3. Shaikh H, Zulfiqar H, Mewawalla P: Evans syndrome. Treasure Island (FL): StatPearls Publishing; 2019. <https://www.amjcaserep.com/abstract/index/idArt/920760>
4. Teachey DT, Manno CS, Axsom KM, Andrews T, Choi JK, Greenbaum BH, et al. Unmasking Evans syndrome: T-cell phenotype and apoptotic response reveal autoimmune lymphoproliferative syndrome (ALPS). *Blood* 2005;105:2443-8.
5. Pui CH, Wilimas J, Wang W. Evans syndrome in childhood. *J Pediatr.* 1980; 97 (5):754-8.
6. Wang WC. Evans syndrome in childhood: Pathophysiology, clinical course, and treatment. *Am J pediatric Hematol Oncol.* 1988; 10(4):330-8.
7. Mathew P, Chen G, Wang W. Evans syndrome: results of a national survey. *J Pediatric Hematol Oncol.* 1997; 19(5):443-7.
8. Savasan S, Warriar I, Ravindronath Y. The spectrum of Evans' syndrome. *Archives of Disease in childhood* 1997; 77(3): 245-8.
9. Momin M, Aluri A, Reddy S, Pasupala NK. Evans' Syndrome-Haemolytic Anemia with Thrombocytopenia- a rare autoimmune disorder. *J ClinSci Res* 2017;6:237-40. DOI: <http://dx.doi.org/10.15380/2277-5706.JCSR.17.08.004>.
10. Michel M, Chanet V, Dechartres A, et al. The spectrum of Evans syndrome in adults: new insight into the disease based on the analysis of 68 cases. *Blood.* 2009;114(15):3167-3172.
11. Jordan M, Schecter, Irene Dy, Jonathan Saniel, Helen rechards, David savage et al. Evans syndrome associated with anti En<sup>a</sup> Antibody leading to fatal Immune Hemolytic Anemia. *Blood* (2009) 114 (22): 3148
12. Patten E, Reuter FP. Evans' syndrome: possible benefit from plasma exchange. *Transfusion.* 1980 Sep-Oct;20(5):589-93. doi: 10.1046/j.1537-2995.1980.20581034517.x. PMID: 7423599.
13. Vaughn JE, Anwer F, Deeg HJ. Treatment of refractory ITP and Evans syndrome by haematopoietic cell transplantation: is it indicated, and for whom? *Vox Sang.* 2016;110(1):5-11.
14. Oyama Y, Papadopoulos EB, Miranda M, Traynor AE, Burt RK. Allogeneic stem cell transplantation for Evans syndrome. *Bone Marrow Transplant.* 2001;28(9):903-905. <https://doi.org/10.1038/sj.bmt.17>