

A rare case of pregnancy in the rudimentary horn of unicornuate uterus: a case report.

Dr. Nikunj Patel¹, Dr. Rekha Kammar², Dr. Mansee Gajjar^{3*}, Dr Akshay Patel⁴

¹Assistant Professor, ^{2,3,4} Resident Doctor, Department of Radiology, B. J. Medical College, Ahmedabad, Gujarat, India.

Abstract:

A rudimentary horn with a unicornuate uterus results due to failure of the complete development of one of the Mullerian ducts and incomplete fusion with the contralateral side. Pregnancy in a rudimentary horn of the uterus is a rare clinical condition and it carries grave consequences for mother and the fetus. The primary strategy of the management is surgical excision of the rudimentary horn. Here is a case of 23 year old, gravida 2 with ruptured non communicating rudimentary horn pregnancy at gestational age 19 weeks presented with severe abdominal pain and rudimentary horn pregnancy was diagnosed on USG and MRI. Laparotomy was done and dead fetus with placenta delivered followed by excision of the rudimentary horn. The post-operative period was uneventful. This highlights the need of an increased awareness of this condition especially in developing countries where most pregnancy is unbooked and uninvestigated. The use of ultrasonography helps clinicians to diagnose uterine malformations earlier, which can then be confirmed by a magnetic resonance image (MRI) or a laparoscopy.

Keywords: Magnetic Imaging Resonance, Rudimentary horn, Rupture, Ultrasound.

Introduction:

Mullerian anomalies were first classified in 1979 by Buttram and Gibbons and further revised by the American Society of Reproductive Medicine (ASRM) in 1988. According to ASRM, unicornuate uterus is a type 2 classification with unilateral hypoplasia or agenesis that can be further sub-classified into communicating, non-communicating, no cavity, and no horn⁽¹⁾. Latest classification of Mullerian anomalies by ESHRE-ESGE (Grimbizis et al) classify unicornuate uterus to Class U4a/Hemi uterus with a rudimentary (functional) cavity⁽²⁾.

Mullerian duct anomalies result from defective fusion, canalization or absorption of the median septum of the female reproductive system during embryonic development. Pregnancy in rudimentary horn is a rare condition that can lead to a most dreaded outcome when it ruptures. The majority of cases are diagnosed late, after the rupture has occurred. The use of ultrasonography helps clinicians to diagnose uterine malformations earlier, which can then be confirmed by a

*Corresponding Author:

Dr. Mansee Gajjar

Email: gajjarmansee@gmail.com

QR Code:



magnetic resonance image (MRI) or a laparoscopy. The standard treatment for a rudimentary horn pregnancy is surgical excision to prevent complications and recurrence ⁽³⁾.

Case Report:

A 23-year-old female presented at 19 weeks’ gestation and was referred to the CIVIL Hospital, Ahmedabad, with a suspicion of abdominal pregnancy with viable fetus. Pregnancy was misdiagnosed as intraabdominal pregnancy by ultrasound in a peripheral center and the case was later referred to our hospital. The patient was gravida 2, para 1, with one previous caesarean section delivery at term approximately 17 months previously. The caesarean section was indicated due to oblique fetal lie. No documents were available.

At admission, the patient’s general condition was good and her vital signs were normal. A physical examination of the abdomen revealed a relaxed, non-tender uterus palpable to the level of the umbilicus.

A transabdominal ultrasound showed a single, viable fetus above and on the left of empty uterus with fetal parameters corresponding to 19 weeks’ gestation with mild free fluid in peritoneal cavity. The amniotic fluid was normal and the placenta was posterior in the lower segment. Pregnancy in a rudimentary horn of the uterus was suspected with a differential diagnosis of an abdominal pregnancy.

Image 1: Ultrasonography showing Empty Uterus and pregnancy to the above and left side

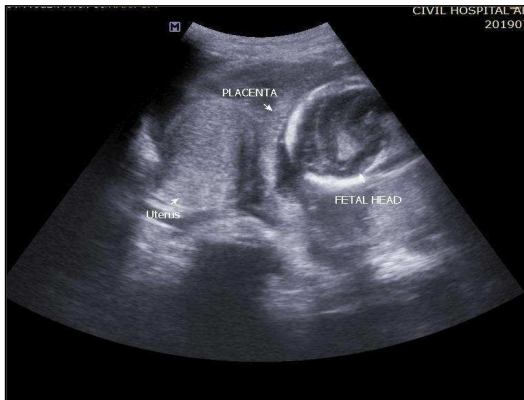

Image 2: Ultrasonography showing myometrial tissue surrounding pregnancy.

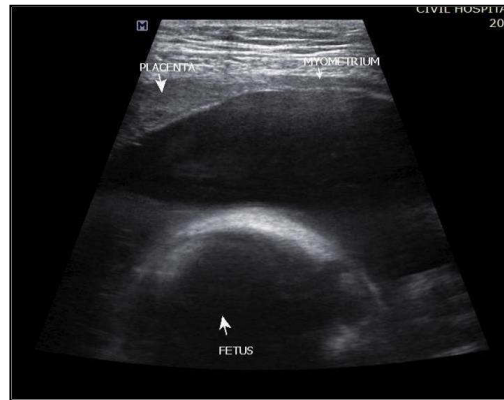

Image 3 MRI Pelvis coronal FAT/SAT showing normal Uterus and pregnancy to the above and left side.

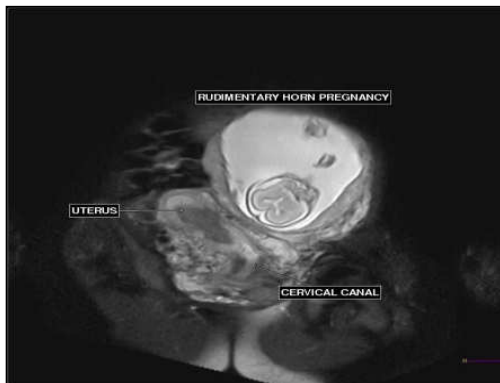
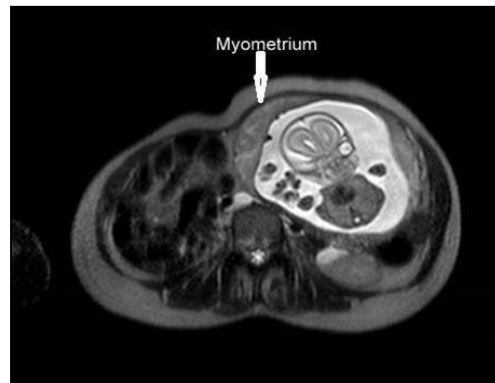


Image 4 MRI Pelvis Axial T2 WI/ TSE showing myometrial tissue surrounding pregnancy.



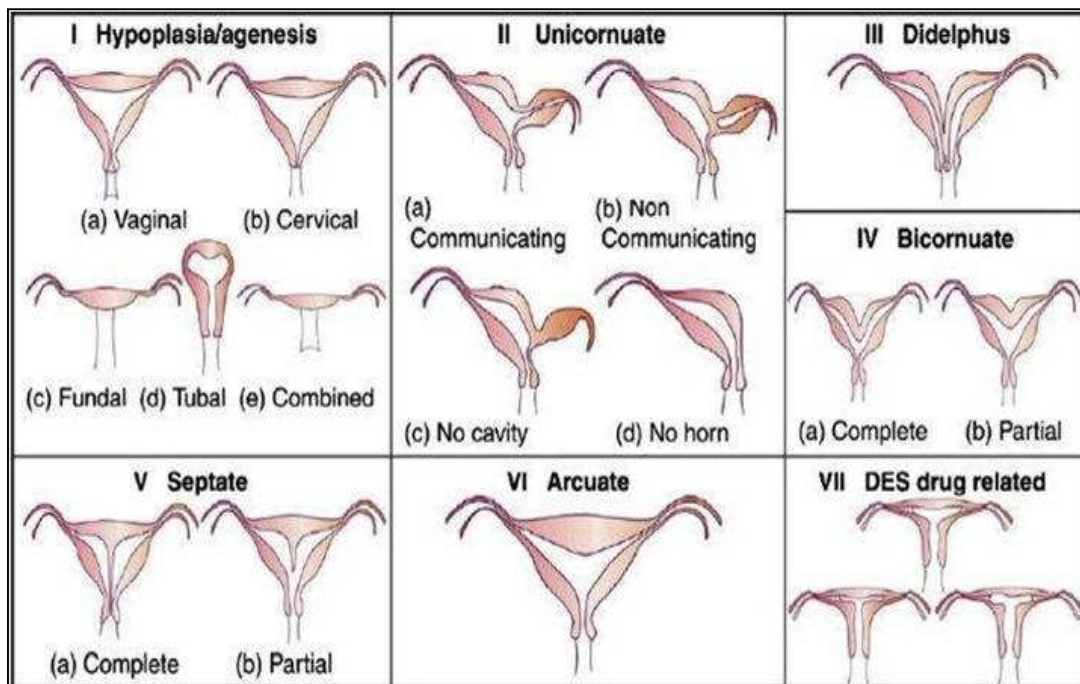
As the patient's vitals were stable, MRI pelvis was advised. MRI of the pelvis confirmed the diagnosis of pregnancy in the rudimentary horn of the uterus, as normal myometrial tissue was seen around the fetus; however, pregnancy in one horn of a bicornuate uterus could not be definitively excluded.

The patient underwent a laparotomy through a midline infra-umbilical incision. Preoperatively, haemoperitoneum was present. The findings included a unicornuate uterus with a normal ovary and fallopian tube on the right side. The pregnancy was in a rudimentary horn on the left side with serosal dehiscence, with a normal ovary and fallopian tube attached to it; it was classified as non-communicating rudimentary horn. Fetus with placenta was removed from rudimentary horn and rudimentary horn was excised. Postoperatively 2 pint PCV was transfused. A histopathology examination confirmed the diagnosis. There was no infiltration of the chorionic villi into the myometrium.

Discussion:

Pregnancy in a rudimentary horn was first described by Mauriceau and Vassal in 1669. The reported incidence is 1 in 100,000 to 140,000 pregnancies⁽⁴⁾. The most accepted explanation is the transperitoneal migration of the sperm cells or a fertilised ovum⁽⁵⁾. This explanation was supported by the observation of the *corpus luteum* in the contralateral ovary. It is extremely uncommon for such cases to result in a viable baby. These cases usually result in the rupture of the horn in the second or third trimester, typically between the 10th and 20th week of gestation⁽⁶⁾. Only 10% of cases such as these reach term, and the fetal salvage rate is only 2%⁽⁷⁾. The rupture occurs because of the underdevelopment of the myometrium and a dysfunctional endometrium.

Image 5 American Society of Reproductive Medicine (ASRM) Classification of Uterine Mullerian anomalies



The anatomical variations of a rudimentary horn are useful for the classification of a unicornuate uterus by the American Society of Reproductive Medicine (ASRM). Acien *et al.*

performed a systematic review to analyse the classification systems for uterine anomalies and concluded that an embryological clinical classification system seemed to be the most appropriate. This case report presents a case from class II, and would be classified as class IIB according to the ASRM.⁽⁸⁾

Tsafrir *et al.* suggested the following criteria for diagnosing a pregnancy in the rudimentary horn: (1) a pseudo pattern of asymmetrical bicornuate uterus; (2) absent visual continuity between the cervical canal and the lumen of the pregnant horn, and (3) the presence of myometrial tissue surrounding the gestational sac⁽⁹⁾. Ultrasound sensitivity remains only 26 %⁽¹⁰⁾. The enlarging horn with the thinned myometrium can obscure the adjacent anatomical structures and the sensitivity further decreases as the gestation progresses. MRI has proven to be a very useful diagnostic tool.

Approximately 38% of patients have coexisting renal abnormalities. Unilateral renal agenesis is most commonly found; this is always ipsilateral with the rudimentary horn⁽¹¹⁾. The differential diagnosis includes a tubal, cornual or intrauterine pregnancy in a bicornuate uterus. Ultrasonographical features may help to reach diagnosis, as in the following examples. A tubal pregnancy will not show a ring of the myometrium surrounding the gestational sac. A variation in the thickness of the myometrium in two horns and a marked distance between them favour the diagnosis of a rudimentary horn pregnancy. The continuity between the endometrium lining the gestational sac and the other uterine horn is typical for a pregnancy in a bicornuate uterus.⁽⁹⁾

Immediate surgery is recommended whenever a diagnosis of a pregnancy in the rudimentary horn is made. The traditional treatment is a laparotomy and the surgical removal of the pregnant horn to prevent rupture and recurrent rudimentary horn pregnancies. In recent years, several cases have been treated successfully by laparoscopies using various techniques.

Conclusion:

Despite advances in ultrasound technology, the antenatal diagnosis of a rudimentary horn pregnancy remains difficult for inexperienced physicians. MRI has proven to be a very useful diagnostic tool. A high index of clinical suspicion for uterine malformations early in the gestation can reduce the mortality rate, along with early intervention. When a rudimentary horn pregnancy is diagnosed, the excision of the horn with ipsilateral salpingectomy is the recommended surgical treatment for the best prognosis. This case highlights the need for high clinical suspicion of this rare condition.

Declaration:

Written informed consent was obtained from the patient and her husband for the publication of this report, along with the MRI images and photographs.

References:

1. Hassan CH, Karim AK, Ismail NA, MH Omar. Case report of ruptured non communicating right rudimentary horn pregnancy: an acute emergency. *Acta medica (Hradec Kralove)* 2011;54(3): 125-126.
2. Grimbizis GF, Campo R. Congenital malformations of the female genital tract: the need for a new classification system. *Fertil Steril.* 2010; 94 (2):401-7.

3. Buntugu K, Ntumy M, Ameh E, Obed S. Rudimentary horn pregnancy: Pre-rupture diagnosis and management. *Ghana Med J*. 2008; 42:92–4.
4. H. K. Sevtap, A. M. Aral, and B. Sertac, “An early diagnosis and successful local medical treatment of a rudimentary uterine horn pregnancy: a case report,” *Archives of Gynecology and Obstetrics*, 2007 : 275(4); 297–298.
5. M. Scholtz, “A full-time pregnancy in a rudimentary horn of the uterus,” *British Journal of Obstetrics & Gynaecology*, 1951 ;58:293–296.
6. Sönmezer M, Taskin S, Atabekoğlu C, Güngör R, Unlü C. Laparoscopic management of rudimentary uterine horn pregnancy: Case report and literature review. *JLS*. 2006; 10: 396–9.
7. Jain R, Gami N, Puri M, Trivedi SS. A rare case of intact rudimentary horn pregnancy presenting as hemoperitoneum. *J Hum Reprod Sci*. 2010; 3: 113–5.
8. Ación P, Ación MI. The history of female genital tract malformation classifications and proposal of an updated system. *Hum Reprod Update*. 2011; 17:693–705.
9. Tsafrir, N. Rojansky, H. Y. Sela, J. M. Gomori, and M. Nadjari, “Rudimentary horn pregnancy: first-trimester prerupture sonographic diagnosis and confirmation by magnetic resonance imaging,” *Journal of Ultrasound in Medicine*, 2005;24(2):219–223.
10. Y. Jayasinghe, A. Rane, H. Stalewski, and S. Grover, “The presentation and early diagnosis of the rudimentary uterine horn,” *Obstetrics and Gynecology*, 2005; 105-(6): 1456–1467.
11. Park JK, Dominguez CE. Combined medical and surgical management of rudimentary uterine horn pregnancy. *JLS*. 2007; 11:119–22.