

First Dorsal Metacarpal Artery (FDMA) flap: A reliable choice for thumb defects.

Dr. Nilesh Ghelani¹, Dr. Sankit Shah², Dr. Arvind Kaushal^{3*}, Dr. Hardik Ponkiya⁴

¹Associate professor, ²Assistant professor, ^{3,4}M.ch.Resident Department of Burns and plastic surgery, Smt. SCL hospital, Saraspur, Smt. NHL Medical College, Ahmedabad, Gujarat -380018.

Abstract:

Introduction: - Soft tissue defects of thumb are very debilitating, and require a good durable coverage to give a functional thumb to the patient. Lots of options are available for thumb reconstruction. In this study we focused on FDMA flap to cover the defects. **Material and Methods:-** A prospective study of 15 patients which presented with small and medium size soft tissue defects of thumb over the period of 2 year are managed with FDMA flap along with treatment for associated injuries and are subsequently evaluated for outcome and followed upto 3 months. **Results:** - We are able to cover the defects easily in all patients without any undue tension. All flap survived, two developed distal margin necrosis and one developed epidermal loss, and they were managed with dressings. Donor site covered with STSG and wound over dorsum closed primarily. **Conclusion:** - With careful dissection, FDMA flap is easy to harvest. It provides reliable, durable and sensate cover with minimal donor site morbidity.

Keywords:- Cross finger type, FDMA flap, islanded type, Thumb defect.

Introduction:

During the evolution what humans got is specialized function of thumb, which aid in grasping, opposing and other specialized functions. Soft tissue defects of thumb are very debilitating and results in more loss of function than injury to any other finger¹. So, soft tissue defects of thumb must be provided with reliable, durable and sensate cover to ensure good functionality of the thumb.

Many options are available to reconstruct the defects such as homodigital local flaps like V-Y advancement flap, Moberg's flap, heterodigital local flaps like Littler's flap, cross finger flap, distant or regional flaps like reverse radial forearm flap, groin flap, and microsurgical free tissue transfer like pulp tissue transfer of toe and other small free flaps. In this study we focused on FDMA flap for small and medium size thumb defects and its outcomes.

FDMA flap was first described by Hilgenfeldt in 1961 and Holveich in 1963 as a peninsular flap with preservation of skin over pedicle². In 1979 Foucher and

* Corresponding Author:

Dr. Arvind Kaushal

Email: dr.arvindkaushal@gmail.com

QR Code:



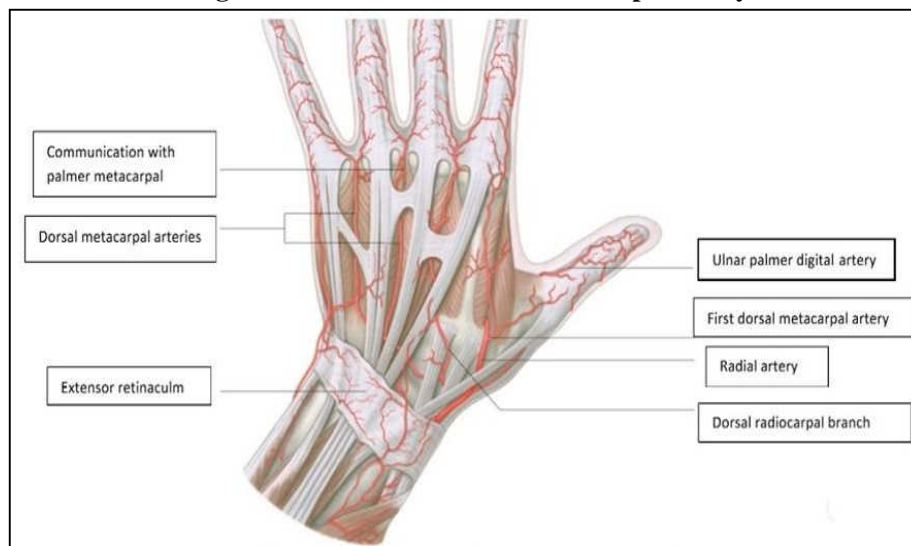
Braun described it as an island flap³.

Relevant Anatomy:

The first dorsal metacarpal artery (Image-1) arises from the radial artery just before it passes between the heads of the first dorsal interosseous. It divides almost at once into two branches which supply the adjacent sides of the thumb and index finger as far distally as the proximal interphalangeal joint.

In the majority of cases the first dorsal metacarpal artery follows a fascial course overlying the first dorsal interosseous and parallel to the second metacarpal bone. Occasionally it may follow an intramuscular course. Distally, over the proximal phalanx, it anastomosis with the dorsal branches of the radiopalmar digital artery of the index finger⁴.

Image 1: Course of first dorsal metacarpal artery⁴.



Material and Methods:

This prospective study was performed at our institution from Jan 2016 to April 2018, during this period 15 patient presented with soft tissue defect of the thumb. They all are evaluated and planned for FDMA flap.

Surgical technique:

Out of 15 patients 14 are done under regional anaesthesia and one under general anaesthesia. Tourniquet was used in all patients. First thorough debridement was done. Associated bony injuries are fixed properly. Then size of defect is measured and extrapolated on the dorsum of the index finger. Planning in reverse was done to ensure flap reaches and cover whole the defect easily and tension free.

For **islanded type flap**, then incision is placed first over dorsum of index finger and flap is elevated from distal to proximal and carefully above the paratenon of extensor tendon and dissection continues once we reached the proximal limit, then a lazy S incision is placed over dorsum of the hand. Dermal flap are raised on both the side of the incision. Next flap is lifted and dissection continues proximally carefully dissecting the pedicle. At this stage one

can see the first dorsal interossei muscle and we include some fibers the muscle to ensure no damage was done to pedicle. Once flap is elevated, tourniquet was released and flap is check for bleeding. Then a subcutaneous tunnel was made and flap is transferred to defect site and inset given.

For **cross finger type flap**, after extrapolating defect size on dorsum of index finger, incision is given first on ulnar side and then proximal and distal incision were given. Flap is elevated from ulnar to radial side carefully above the paratenon of extensor tendon till base is reached. Flap is then turned and inset given. Donor site is covered with STSG and incision over dorsum closed primarily. Dressing was done. Post operatively hand elevation is done for 48hrs. All patients were discharged after graft dressing on the 5th post-operative day. Sutures were removed on 10-14th post-operative day. This was followed by a course of physiotherapy for 6 weeks in all patients. The patients were instructed to come for post-operative follow up every month for 3 months. All patients were evaluated for the occurrence of early post-operative complications in terms of flap necrosis, hematoma, infection, wound dehiscence and graft loss.

Results:

During this period, fifteen 1st dorsal metacarpal artery flaps were used for reconstruction of soft tissue thumb defects in 15 cases. The subject data and outcomes are summarized in Table 1.

Table1: Clinical data

Sr. No.	Age/sex	Flap Size(mm)	Defect site	Flap type	Associated injury	complication
1	45y/M	26x13	Rt dorsal	Islanded	nil	nil
2	50y/M	24x14	Lt dorsal	Islanded	nil	nil
3	26y/M	29x18	Rt dorsal	Islanded	nil	nil
4	55y/M	31x22	Rt dorsal	Islanded	IP joint. Disruption & tendon injury	nil
5	7y/F	21x13	Rt dorsal	Islanded	IP joint disruption	Distal half epidermal loss
6	45y/M	29x21	Rt volar	Islanded	Distal half amputation	Distal margin necrosis
7	48y/M	21x17	Rt volar	Cross finger	nil	nil
8	44y/F	25x17	Rt volar	Islanded	nil	nil
9	40y/M	23x19	Lt volar	Cross finger	nil	nil
10	35y/M	27x21	Lt dorsal	Islanded	Distal half amputation	Distal margin necrosis
11	37y/F	24x20	Rt dorsal	Islanded	nil	nil
12	32y/M	26x19	Rt volar	Cross finger	nil	nil
13	39y/M	23x18	Rt volar	Cross finger	Tip amputation	nil
14	33y/M	29x22	Lt dorsal	Islanded	nil	nil
15	47y/M	25x18	Rt dorsal	Islanded	nil	nil

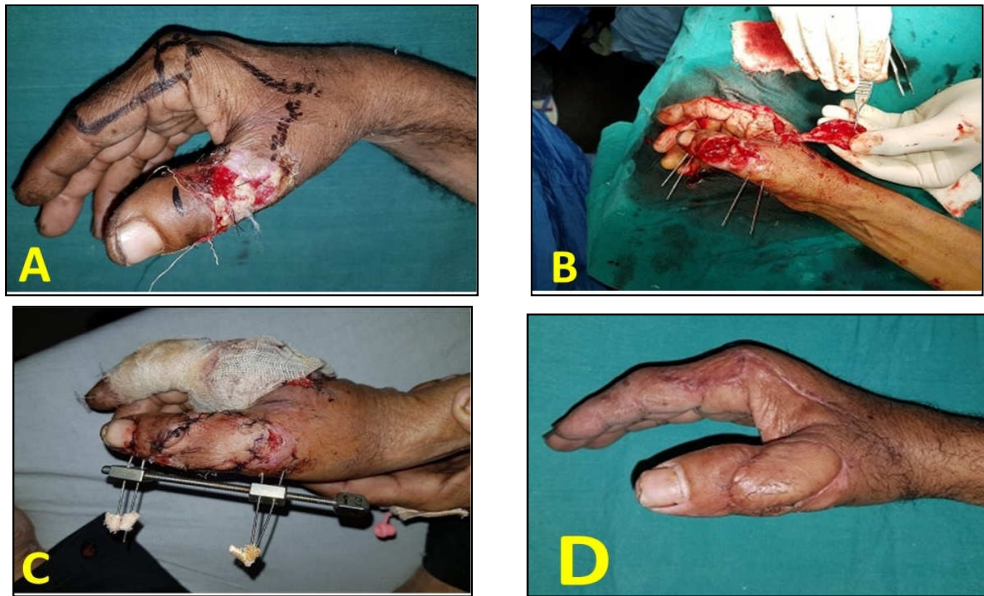
Age of the patients ranges from 7-55years with an average age of 38.8 years. The flap sizes ranged from 21×13 mm to 31x22 mm (mean 25.5×18.1mm). Eleven flap were pedicle type while four were cross finger type. Twelve flaps survived completely and two had distal

flap margin necrosis that was treated conservatively and healed by secondary intention, and one had distal half epidermal loss, which again manage by dressings. All the recipient and donor areas were healed uneventfully. The mean follow-up period was 5.6 months (range 3-10 months). They were pleased with the cosmetic appearance of the flap and donor site.

Case 1:

A 55yr old male presented with h/o road traffic accident, resulting in defect over dorsum of right thumb with IP joint disruption, he was managed with distraction and FDMA flap, and has good post-operative recovery and he was able to do his routine work (Image-2).

Image 2: Case 1 of FDMA flap



(A) Defect over dorsum of RT thumb with flap markings, (B) intra-operative bony fixation with flap elevation, (C) After 7th post-operative day, (D) After 3 month with good aesthetically appearing flap.

Case 2:

A 45 yrs old male presented with partial amputation of RT thumb at IP joint, initially managed with replantation, which eventually fail. Later on distal amputation of RT thumb and coverage with FDMA flap was done. Has good recovery, and able to do his routine work (Image-3).

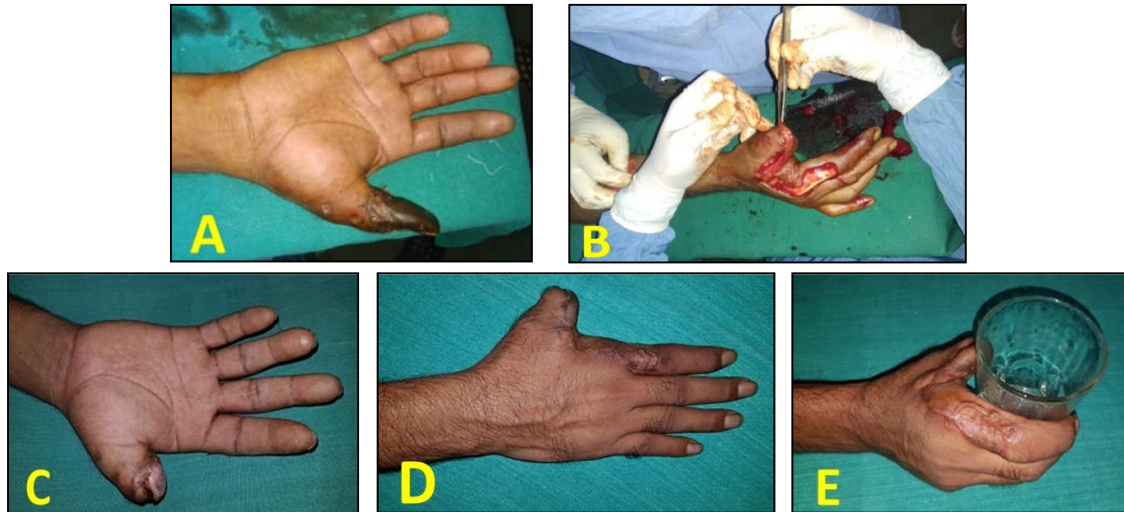
Case 3:

A 7yr old female presented with defect over dorsum of the right thumb along with thumb IP joint disruption, patient was treated with FDMA flap and K-wire fixation of IP t was done (Image-4).

Case 4:

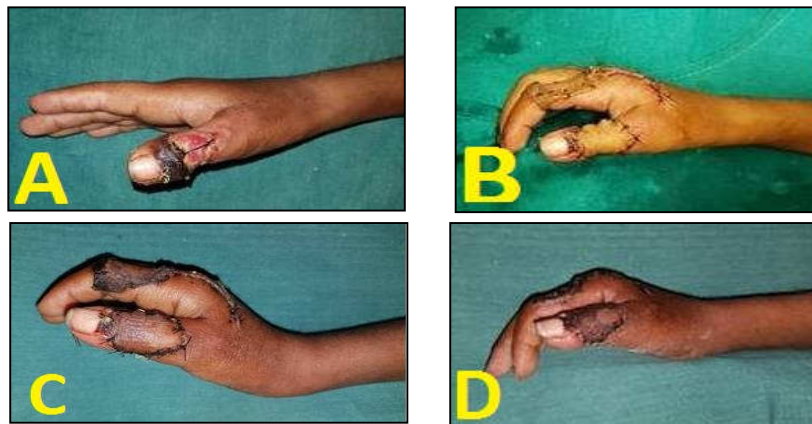
A 33tr old male presented with traumatic amputation of left thumb with exposed bone, was treated with FDMA flap (Image-5).

Image 3: Case 2 of FDMA flap



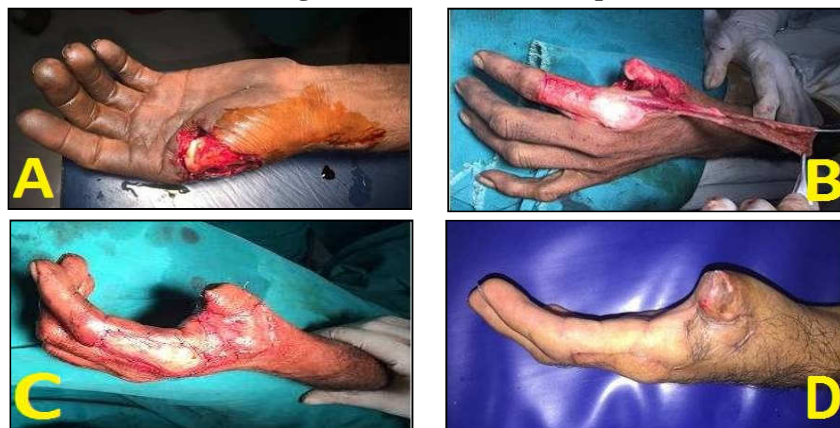(A) Right distal thumb gangrene, (B) after distal amputation and flap elevation, (C) distal margin necrosis, (D) Well healed flap and donor site after 3 months, (E) patient is able to hold glass and do his routine work.

Image 4: Case 3 of FDMA flap



(A) Right thumb dorsal defect, (B) immediate post op after flap inset, (C) 7th post op day, (D) after 3 weeks

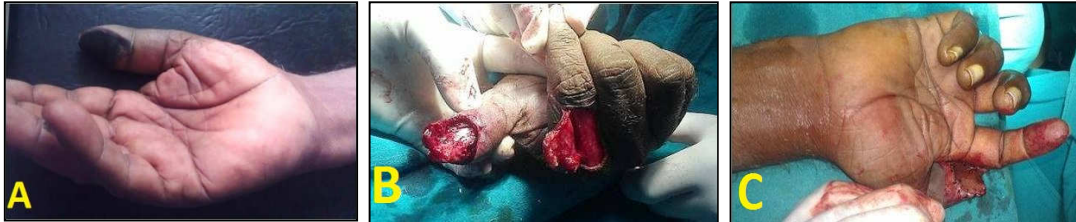Image 5: Case 4 of FDMA flap



(A) Left thumb defect with exposed bone, (B) harvested FDMA flap, (C) after inset, (D) 3 weeks post op. well healed flap

Case 5:

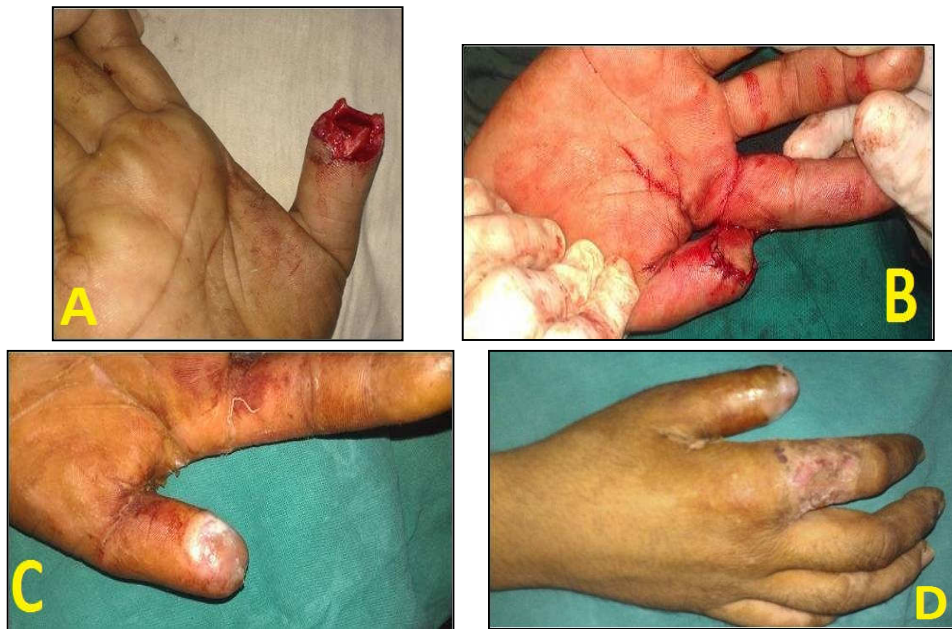A 39y old male presented with gangrene over volar side of RT thumb, which was debrided and defect covered with cross-finger type of FDMA flap (Image-6).

Image 6: Case 5 of FDMA flap

(A) Right thumb volar skin gangrene, (B) After debridement and elevation of cross-finger type of FDMA flap, (C) After inset

Case 6:

A 32yr old male presented with distal tip amputation of RT thumb which was treated with cross finger type of FDMA flap (Image-7).

Image 7: Case 6 of FDMA flap

(A) Right thumb volar defect after traumatic amputation, (B) After cross finger type FDMA flap harvest & inset, (C) After 3 weeks well healed flap and (D) After 3 weeks well healed donor site

Discussion:

There are many options available to cover the thumb defects ranging from local, regional and distal flaps such as Moberg's flap, Littler's Neurovascular Island flap, cross finger flap, pulp tissue transfer of toe and other small free flaps and groin flap, abdominal and other distant flap. All the above mentioned options have their merits and demerits. Local flaps offer superior esthetic results due to replacement "like with like" tissue⁵.

In this study we focused on FDMA flap to cover small and medium size thumb defects and its outcomes. Defect site was volar in 6 patients and dorsal in 9 and we were able

to cover the defect in all the patients, without any undue tension. Twelve out of fifteen flaps survived completely. Two developed distal margin necrosis, which was managed with dressing and one developed loss of epidermal tissue over distal half of the flap, which again managed with dressing.

Ghoraba et al⁶, in their study of 15 flaps, 14 flaps survived completely while one developed distal necrosis and they also managed it with dressings. Satish et al⁷ used 9 FDMA flaps to cover post-traumatic thumb defects and found that the mean flap size was 33.3×19.4 mm and only one flap had partial necrosis that healed without secondary procedure. In our study 12 flaps survived completely, which is comparable and mean size is 25.5×18.1mm.

As compared to groin and abdominal flap, FDMA flap has much advantage with minimal donor site morbidity and also we need not to immobilize the hand in awkward position and also stiffness of joints occurring as a result can be avoided.

In our study donor site is covered with split thickness skin graft, which heals without any complication and there is no morbidity related to donor site. Ratcliffe et al.⁸ and Cilet al⁹, in their respective studies also have no morbidity related to donor site.

Conclusion:

We conclude that, FDMA flap is a good option for thumb defect reconstruction as it provides “local and like” tissue and with no donor site morbidity. Flap is easy to harvest and is able to cover the most of the small and medium size defects, whether dorsal or volar.

References

1. Lai CH, Lai CS, Huang SH, Lin SD, Chang KP. Free medial plantar artery perforator flaps for resurfacing of thumb defects. *Ann Plast Surg* 2010; 65:535–40.
2. Holevich J. A new method of restoring sensibility to the thumb. *J Bone Joint Surg.* 1963; 45:496-502.
3. Foucher G, Braun JB. A new island flap transfer from the dorsum of the index to the thumb. *Plast Reconstr Surg.* 1979; 63:344-9.
4. Standring S, Ellis H, Healy JC, Johnson D, Williams A. *Gray's anatomy: the anatomical basis of clinical practice.* 2005:39:926, 890.
5. Hurren J, Cormack G. The application of the rotation flap to the dorsum of the hand. *Br J Plast Surg* 2000;53:491-4.
6. Ghoraba SM, Mahmoud WH. Outcome of Thumb Reconstruction Using the First Dorsal Metacarpal Artery Island Flap. *World J Plast Surg* 2018; 7(2):151-158.
7. Satish C, Nema S. First dorsal metacarpal artery islanded flap: A useful flap for reconstruction of thumb pulp defects. *Indian J Plast Surg* 2009;42:32-5.
8. Ratcliffe RJ, Regan PJ, Scerri GV. First dorsal metacarpal artery flap cover for extensive pulp defects in the normal length thumb. *Br J Plast Surg* 1992; 45:544–6.
9. Cil Y, Eski M, Isik S. First dorsal metacarpal artery adipofascial flap for thenar burn contracture releasing. *Burns* 2008; 34:127-30.