

# Riedel's Lobe as Morphological Variations of the Human Liver and its Clinical Implications

Dr Manisha Chaudhari<sup>1\*</sup>, Dr H. R. Jadav<sup>2</sup>, Dr T. C. Single<sup>3</sup>

<sup>1</sup> Associate Professor, Department of Anatomy, Dr. M.K.Shah Medical College, Chandkheda, Ahmedabad, India

<sup>2</sup> Professor, Department of Anatomy, Dr M. K. Shah Medical College, Chandkheda, Ahmedabad, India

<sup>3</sup> Dr. T.C.Single Professor and Head, Department of Anatomy, Dr. M. K.Shah Medical College, Chandkheda, Ahmedabad, India.

**Corresponding Author:** Dr Manisha. L. Chaudhari

**Email:** drmanishachaudhari6@gmail.com



## Abstract:

**Background:** liver is a soft, friable and largest gland in the body, occupying the upper part of the abdominal cavity just beneath the right hemidiaphragm. The greater part of it is situated under cover of the ribs, extending to the left to reach the left hemidiaphragm. To study on riedel's lobe as morphological variations of the human liver and its clinical implications. **Materials and method:** A total of 32 formalin-fixed adult human livers, irrespective of the sex, were studied over a period of three years from Dr. M. K.Shah Medical College. These livers were specifically observed for any riedel's lobe morphology. **Results:** out of 32 specimens, 22 were considered normal without any accessory lobes, 10 liver are present with riedel's lobe. **Conclusion:** Riedel's lobe is no longer mistaken for an abdominal tumor by using imaging. However, the condition of "Riedel's lobe" or the extreme case of a downward elongated right hepatic lobe still seems important since the recognition of its existence leads to the correct diagnosis of right abdominal palpable mass, or correct depiction of the tumors within the lowest part of the elongated normal liver.

**Key words:** Accessory lobe, Liver, riedel's lobe, Variations.

## Introduction

Liver is a soft, friable and largest gland in the body, occupying the upper part of the abdominal cavity just beneath the right hemidiaphragm. The greater part of it is situated under cover of the ribs, extending to the left to reach the left hemidiaphragm. It is divided into anatomical right large and left small lobes by the attachment of the peritoneum of the falciform ligament. The right lobe is further divided into quadrate and caudate lobes by the presence of the gallbladder, the fissure for the ligamentum teres, the inferior vena cava, and the fissure for the ligamentum venosum. The fundus of the gallbladder usually projects beyond the inferior border of the liver.<sup>1</sup>

The hepatic (liver) bud appears in the middle of the 3rd week of development as an outgrowth of the endodermal epithelium at the caudal end of the foregut. This hepatic diverticulum consists of rapidly proliferating cells that penetrate the septum Transversum.<sup>2</sup> A thorough knowledge of both the normal

and anomalous or variant surface features of the liver is essential while dealing with a case of an unknown abdominal mass. Hepatic anomalies can be due either to defective development or excessive development of the liver. The latter leads to formation of accessory lobes and fissures on the hepatic surface.<sup>3</sup> One of the abnormalities reported several times is the Riedel's lobe, defined as a downward tongue-like projection of the anterior edge of the right liver lobe to the right of the gallbladder.<sup>4</sup> This variant draws attention in the clinical practice, as it can be mistaken for a tumor due to its elongated aspect. Riedel's lobe appears to be a common variant of normal anatomy, its prevalence being dependent on age-related changes in liver size and skeletal shape.

### Material & Method

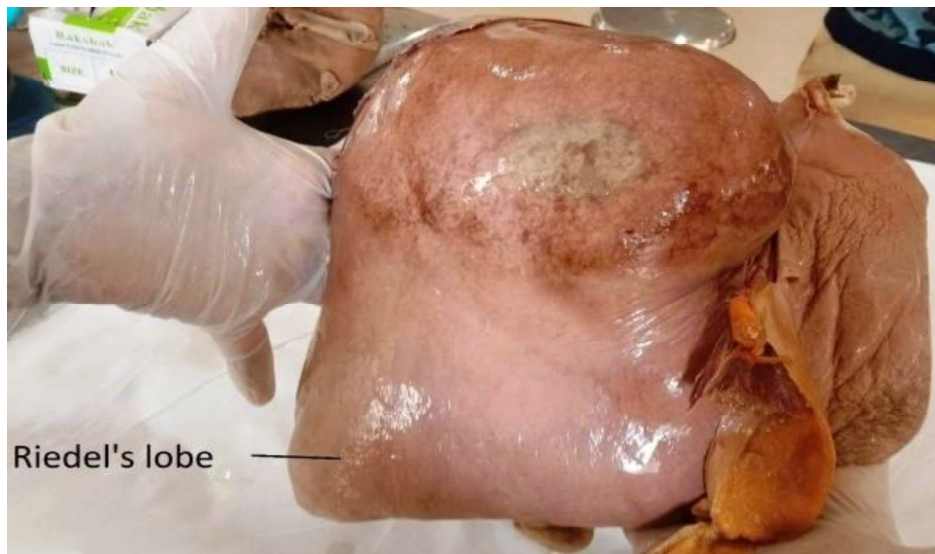
A total of 32 formalin-fixed adult human livers, irrespective of the sex, were studied over a period of three years from Dr. M. K. Shah Medical College. These livers were specifically observed for any variant or anomalous surface morphology like Riedel's lobe. In this study we focus only on the present and absent of Riedel's lobe not other morphological variation.

### Results

**Table 1: Presence of Riedel's lobe in liver**

Morphological variation of liver	Specimen Number	Percentage
Normal liver	22	68.75%
Riedel's lobe	10	31.25%
Total	32	100

**Figure 1: Riedel's lobe (Gross)**



### Discussion

In 1888, Riedel described a tongue-like elongation of hepatic segments V and VI that now carries his name.<sup>5</sup> The etiology of Riedel's lobe has been widely debated, with studies supporting a congenital or acquired origin. The congenital origin is supported by possible defects in the development of the hepatic bud, which can lead to the formation of infra-hepatic accessory lobes. The acquired origin, however, has its roots with Riedel, who attributed the lobe's presence to age-related hepatic modifications, secondary injury from surgical intervention, and intraperitoneal inflammation/chronic cholecystitis, especially with the gallbladder's anatomical relation.<sup>6</sup> No studies were found regarding livers that contain both Riedel's

lobe and other liver projections, which could represent a unique finding that is not normally seen or diagnosed. Riedel's lobe and other liver projections are typically asymptomatic and clinically latent. Inflammation or torsion of these areas may elicit right hypochondriac and/or epigastric pain, which can easily be attributed to more common origins or be mistakenly attributed as idiopathic.<sup>7,8,9</sup>

For definitive diagnosis, common tests include ultrasound, computerized tomography (CT), and magnetic resonance imaging (MRI). Radionuclide imaging and arteriographic examination may also be appropriate to depict possible cancerous lesions and abnormal vascular/cystic features.<sup>10</sup>

Another important point is that there are some case reports on torsion of Riedel's lobe, which were resected surgically.<sup>11</sup> Riedel's lobe is usually separated from the rest of the liver by a transverse narrowing of the hepatic parenchyma. However, Riedel's lobe is occasionally attached to the liver by a wide fibrous sulcus. In these conditions it is regarded as a pedunculated lobe which can undergo torsion.<sup>12</sup>

The incidence of Riedel's lobe observed in radiologic images ranges from 3.3% to 14.5% in the literature.<sup>13,14</sup> Such wide range of prevalence may be due to existence of several definitions in the literature and the absence of standardization of diagnostic criteria on imaging. The definition of Riedel's lobe was based on its morphologic forms and included all types of hypertrophic right liver formations extending below the inferior costal margin.

Complications: An accessory lobe, including Riedel's lobe can mimic a mass in the right hypochondrium with symptoms such as pain, vomiting, constipation, or bloating.<sup>15</sup> Differential diagnosis includes enlarged kidney, gallbladder, liver tumor or other abdominal tumor (such as right colonic tumor). In addition to this, torsion, bleeding and extrinsic compression of the stomach are associated with Riedel's lobe. In the literature, it is also referred as floating lobe, "tongue like," or constriction lobe (Riedel, 1988). Generally, Riedel lobe can be presented with minor symptoms such as an abdominal discomfort due to the extrinsic compression and torsion episodes or without any symptom. Its differential diagnosis includes all causes of palpable normal liver such as emphysema, right-sided pleural effusion, congestive heart failure, thin body carriage, and deep diaphragmatic excursion or other liver diseases such as cirrhosis, hepatic, or metastatic cancer.<sup>16</sup> An additional management of this normal anatomical feature is proposed to consider it as a possible source of a "living-related" hepatic transplant.

## Conclusion

Riedel's lobe seems to be a simple anatomical variation secondary to inflammation or attachment to other tissue rather than a congenital anomaly. The term "Riedel's lobe" has clinically become less important due to the progress of several imaging technologies. Riedel's lobe is no longer mistaken for an abdominal tumor by using imaging. However, the condition of "Riedel's lobe" or the extreme case of a downward elongated right hepatic lobe still seems important since the recognition of its existence leads to the correct diagnosis of right abdominal palpable mass, or correct depiction of the tumors within the lowest part of the elongated normal liver.

## References

1. Snell RS; *Clinical Anatomy by Regions*; 9th Ed.; Philadelphia: Wolters Kluwer Lippincott Williams & Wilkins; 2012: 196-197.
2. Sadler TW; *Langman's Medical Embryology*; 11th Ed.; Philadelphia: Wolters Kluwer Lippincott Williams & Wilkins; 2010: 219.
3. Champetier J, Yver R, Letoublon C, Vigneau B. A general review of anomalies of hepatic morphology and their clinical implications. *Anatomia Clinica*. 1985 Dec;7(4):285-99.
4. Zamfir R, Brasoveanu V, Boros M, Herlea V, Popescu I. Hepatocellular carcinoma in Riedel's lobe. *Chirurgia*. 2008;103(1):121-3.
5. Riedel I. Über den zungenförmigen Forsatz des rechten Leberlappens und seine pathognostische Bedeutung für die Erkrankung der Gallenblase nebst Bemerkungen über Gallenstein Operationen. *Berl Klin Wochenschr* 1888;29:577—81.
6. KUDO M. Riedel's lobe of the liver and its clinical implication. *Internal Medicine*. 2000;39(2):87-8.

7. Lefaucher C, Dupuis E, Muller J, Laham A. Torsion of Riedel's lobe. Two cases (author's transl). *Journal de Chirurgie*. 1978 Jan 1;115(1):25-8.
8. Khan AM, Hundal R, Manzoor K, Dhuper S, Korsten MA. Accessory liver lobes: a diagnostic and therapeutic challenge of their torsions. *Scandinavian journal of gastroenterology*. 2006 Jan 1;41(2):125-30.
9. Yano K, Ohtsubo M, Mizota T, Kato H, Hayashida Y, Morita S, Furukawa R, Hayakawa A. Riedel's lobe of the liver evaluated by multiple imaging modalities. *Internal medicine*. 2000;39(2):136-8.
10. Yeh CN, Lee WC, Jeng LB, Chen MF. Pedunculated hepatocellular carcinoma: clinicopathologic study of 18 surgically resected cases. *World journal of surgery*. 2002 Sep;26(9):1133-8.
11. Champetier J, Yver R, Letoublon C, Vigneau B. A general review of anomalies of hepatic morphology and their clinical implications. *Anatomia Clinica*. 1985 Dec;7(4):285-99.
12. Baum S, Locko RC, d'Avignon MB. Functional anatomy and radionuclide imaging: Riedel's lobe of the liver. *Anat Clin*. 1982; 4:121–123.
13. Sham R, Sain A, Silver L. Hypertrophic Riedel's lobe of the liver. *Clin Nucl Med*. 1978; 3: 79–81.
14. Sangeetha A, Kumar SN. Morphological variations of the liver and its applied significance: A cadaveric study. *Journal of Datta Meghe Institute of Medical Sciences University*. 2021 Apr 1;16(2):303.
15. James Jr PM, Howard JM, Wolferth Jr CC. Riedel's lobe of the liver. *The American Journal of Surgery*. 1963 Jun 1;105(6):812-5.
16. Savopoulos C, Kakaletsis N, Kaiafa G, Iliadis F, Kalogera-Fountzila A, Hatzitolios AI. Riedel's lobe of the liver: a case report. *Medicine*. 2015 Jan;94(3).